Infectious Diseases Laboratory

College of Veterinary Medicine

UNIVERSITY OF GEORGIA

Fall/Winter 2023-2024

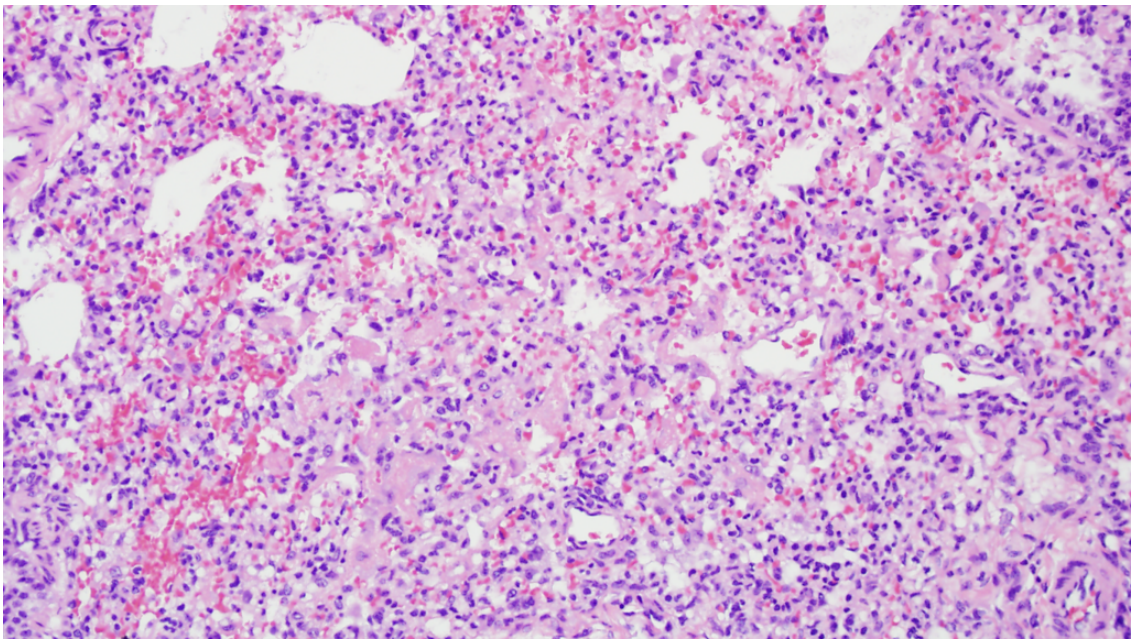

This is ferret lung with an interstitial pneumonia associated with skunk adenovirus and *Streptococcus equi* subsp. *zooepidemicus* infection. Magnification 20X. Hematoxylin and eosin stains.

UGA ZEAPS detects skunk adenovirus-1 in domestic ferrets (*Mustela putorius*)

In early 2019, the UGA Zoo and Exotic Animal Pathology Service, which is co-managed by the Infectious Diseases laboratory, received whole body specimens of three male ferrets (*Mustela putorius*) from a regional pet vendor. The ferrets had arrived at the vendor's facility in two different shipments over about a three-week period; all died within days of arrival at the facility. Per the vendor, the new arrivals

The ZEAPS and IDL teams, working in concert with complementary veterinary diagnostic services at the University of Georgia, identified the likely cause of death in these ferrets as skunk adenovirus-1, or SkAdV-1, which was detected by electron microscopy and validated by other tests. Our diagnosis represents the first identification of SkAdV-1 in ferrets—the seventh species in which this virus has been identified.

Adenoviruses can infect almost all known classes of vertebrates, including humans. A recent study screened 327 published manuscripts for relevance to zoonotic and anthroponotic transmission potential and identified 74 for review; of 24 deemed relevant, 16 demonstrated evidence of zoonotic transmission of AdVs.

Adenoviruses may cross species barriers, even among distantly related species. For instance, canine adenovirus 1 (CAdV-1) has caused disease in 3 mammalian families including foxes, wolves, and coyotes (Canidae); skunks (Mephitidae); and bears (Ursidae).

We encourage you to read our latest study, Detection of skunk adenovirus-1 in domestic ferrets (Mustela putorius), which is published in the January 2024 issue of the Journal of Veterinary Pathology. Co-authors on this study are Maria E. Orbay-Cerrato, Roger Alan Nilsen, Nicole Gottdenker, Rita McManamon, Jessica A. Elbert, Justin M. Stilwell, Mary B. Ard, Branson W. Ritchie, and Brittany McHale.

Orbay-Cerrato ME, Nilsen RA, Gottdenker N, et al. Detection of skunk adenovirus-1 in domestic ferrets (Mustela putorius). Veterinary Pathology. 2024;61(1):135-139. doi:10.1177/03009858231189722

UGA ZEAPS provides access to histopathology and diagnostic services through a team of highly trained, board-certified pathologists with unique expertise in zoological and exotic animal species. All diagnostic work is conducted by the IDL, complementary UGA laboratories, or subcontracting laboratories that meet rigorous standards. ZEAPS is managed by IDL, which is based in the Department of Small Animal Medicine and Surgery, and the Department of Pathology.

For more information about the services offered by ZEAPS and/or IDL, contact us at idl@uga.edu.

Recent Manuscripts

Orbay-Cerrato ME, Nilsen RA, Gottdenker N, McManamon R, Elbert JA, Stilwell JM, Ard MB, Ritchie BW, McHale B. Detection of skunk adenovirus-1 in domestic

Ellis JS, Ritchie BW, McHale B, Rao S, Sadar MJ. Surveillance for Avian Bornavirus in Colorado and Wyoming, USA, Raptor Populations. J Wildl Dis. 2023 Nov 4. https://doi.org/10.7589/JWD-D-22-00118

Nicole Gottdenker, Rafael Ramos,Hassan Hakimi, Brittany McHale, Sam Rivera, Bryce Miller, Elizabeth Howerth, Caitlin Burrell, Justin Stilwell, Rita McManamon, and Guilherme Verocai. Angiostrongylus cantonensis Infection in Brown Rats (Rattus norvegicus), Atlanta, Georgia, United States, 2019–2022. Emerging Infectious Diseases. 29.10 (2023): 2167-2170. https://wwwnc.cdc.gov/eid/article/29/10/23-0706_article

Ji-Hang Yin, Seth Oster, Brittany McHale, Rachel Neto. Naturally occurring psittacid herpesvirus-3 and probable adenovirus co-infection in an Indian ringneck parakeet (*Psittacula krameria*) in the United States. Journal of Veterinary Diagnostic Investigation. 2023 Nov;35(6):772-776. https://journals.sagepub.com/doi/10.1177/10406387231200578

Leach KS, Rivera S, Devlin W, Kutinsky I, Boyd R, Danforth MD, Rapoport G, Yakubinis L, McManamon R, McHale B, Murphy HW. MANAGEMENT OF ATRIAL FIBRILLATION, VENTRICULAR ARRHYTHMIA, LEFT VENTRICULAR DYSFUNCTION, AND SUBSEQUENT CARDIOPATHOLOGIC EVALUATION IN AN ORANGUTAN (*PONGO PYGMAEUS* × *ABELII*). J Zoo Wildl Med. 2023 Jul;54(2):406-411. doi: 10.1638/2022-0031. PMID: 37428707. https://pubmed.ncbi.nlm.nih.gov/37428707/

Bonwitt, Jesse, Madison Riethman, Derel Glashower, Hanna N. Oltean, Ron Wohrle, Brian Joseph, Brittany McHale, and Branson Ritchie. "Application of environmental sampling to investigate a case of avian chlamydiosis in a pet store and breeding facility leading to mass bird exposures." *Zoonoses and Public Health* (2023). https://onlinelibrary.wiley.com/doi/epdf/10.1111/zph.13045

Miller B, Sturmer L, Roberts J. Disseminated neoplasia in cultured hard clams (*Mercenaria mercenaria*). Vet Pathol. 2023 Sep;60(5):624-627. doi: 10.1177/03009858231171665. Epub 2023 May 10. PMID: 37161998. https://doi.org/10.1177/03009858231171665

Imanse SE, Burrell CE, Cannizzo SA, Reilly SA, Rainwater SL, Delaney MA. Neoplasia in an Assurance Population of Puerto Rican Crested Toads (*Peltophryne lemur*). *Vet Path.* 2023. Epub ahead of print. https://doi.org/10.1177/03009858231214029

Chong DLA, McHale B, Garrett KB, Yabsley MJ. Fatal Systemic Haemosporidiosis in a Free-Ranging Greater Sage-Grouse (Centrocercus urophasianus). J Wildl

Emerging Diseases

***Angiostrongylus cantonensis* infection has been identified in Brown Rats (Rattus norvegicus)** from Atlanta, Georgia. Rat lungworm is a zoonotic parasite invasive to the United States and causes eosinophilic meningoencephalitis. For more information on this emerging public health concern, read our study published in Emerging Infectious Diseases: https://wwwnc.cdc.gov/eid/article/29/10/23-0706_article.

We recommend testing for pan-circovirus, as other PBFD-like lesions have been observed in birds (including psittacines) that are not circovirus 1 or circovirus 2. Call the laboratory if you need assistance with diagnosing or managing outbreaks involving any variants of circovirus. 706-542-5812

The **first case of Rabbit Hemorrhagic Disease in Georgia** was documented in a companion rabbit sent to the Infectious Diseases Laboratory's Zoo and Exotic Animal Pathology Service (ZEAPS).

Updates on policies, tests, etc.

We no longer perform the following assays:

- feline heartworm antigen
- Snap 4dx
- rheumatoid factor

IDL's Holiday Schedule

We thank you for your business and wish you and your colleagues a Happy Holiday Season and successful 2024!

increase. Please allow extra time for delivery and please ensure your package is properly addressed:

INFECTIOUS DISEASES LABORATORY
110 Riverbend Rd.
Riverbend North, Rm. 150
University of Georgia
Athens, GA 30602

Our phone numbers:
(706) 542-8092 (office); (706) 583-0843 (Fax); (706) 542-5812 (Lab)

How the holidays impact your shipments and our services:

December and January: The University of Georgia is closed from December 25, 2023, through January 1, 2024. Except for December 25 and January 1, IDL is open during this time, but the UGA closing influences our staffing and all UGA support services. IDL will receive UPS and FedEx packages on December 22 and 26-29. However, we will not receive U.S. mail each day.

Molecular Diagnostic Tests at IDL: IDL will be short-staffed and phone coverage will be reduced. We will complete diagnostic tests as sample volume dictates. We recommend you ship any elective screening samples to arrive prior to December 22 or after January 2.

Histopathology Services through the UGA Zoo and Exotic Animal Pathology Service (ZEAPS): Support services (histopathology processing, some diagnostic tests) through our UGA partners (Pathology Department and Athens Veterinary Diagnostic Laboratory) will be reduced and less predictable from December 26 through December 29. We cannot promise short turnaround for biopsies or STAT samples, and test reporting will be reduced. Please send histopathology cases to arrive prior to December 20 or after January 2. Pathologist availability will be limited to emergencies only. If you need an emergency necropsy or have other concerns, please contact Dr. Brittany McHale on her cell at 815-575-2954 and she will help coordinate your case.

We hope you enjoy your holiday season!

--The Infectious Diseases Laboratory Staff and the ZEAPS Pathologists

Drs. Bran Ritchie, Brittany McHale, Bryce Miller, Caitlin Burrell, Elizabeth Howerth and Nicole Gottdenker, and IDL staff Holly Beach, Kara Huff, Roger Nilsen, Teri Roloson and Carla Foditsch

Our eNewsletters are now archived online!
Click here to visit the UGA IDL eNewsletter archive

Thank you for supporting our work!
Support the UGA New Materials Institute
Support the UGA Infectious Diseases Laboratory and Emerging Diseases Research Group